

## CASE REPORT

### A VARIANT OF WOLF'S ISOTOPIC RESPONSE-OVERRIDING OF TWO BLISTERING DISEASES

Murali Narasimhan<sup>1</sup>, Subashini Karthikeyan<sup>2</sup>, Pushpa Gnanaraj<sup>3</sup>, Venugopal Vakati<sup>4</sup>

#### HOW TO CITE THIS ARTICLE:

Murali Narasimhan, Subashini Karthikeyan, Pushpa Gnanaraj, Venugopal Vakati. "A Variant of Wolf's Isotopic Response-Overriding of Two Blistering Diseases". Journal of Evolution of Medical and Dental Sciences 2015; Vol. 4, Issue 60, July 27; Page: 10553-10555, DOI: 10.14260/jemds/2015/1521

**ABSTRACT:** The term Wolf's isotopic response refers to the occurrence of an unrelated dermatologic disease over the site of an already healed skin disease. The primary disease is usually a healed Herpes zoster scar and the second dermatoses are frequently granulomatous or lichenoid reactions. We report a variant of this phenomenon with co localization of active herpes zoster and Pemphigus vulgaris over the left upper limb as evidenced by the presence of both giant epithelial cells and positive direct immunofluorescence for pemphigus. To the best of our knowledge such an association has not been reported earlier.

**INTRODUCTION:** The term Wolf's isotopic response refers to the occurrence of a new skin disorder at the site of another, unrelated and already healed skin disease.<sup>1,2</sup> Many such conditions have been described. However few uncommon variants of the same phenomena have been described. Here we present one such variant.

**CASE REPORT:** A 60 year old male presented to us with painful blisters in the left arm and forearm of one day duration. The patient had severe burning pain in his left upper limb for 3 days prior to the occurrence of blisters. He was a known case of pemphigus vulgaris, diagnosed 3 years ago and was on regular treatment with oral immunosuppressants including prednisolone in tapering doses and cyclophosphamide 50mg daily. He had been free of skin and mucosal lesions for the past 6 months and was off prednisolone and cyclophosphamide for the past six and four months respectively.

On examination, he had multiple grouped vesicles on an erythematous base distributed on the lateral aspect of left arm and forearm, along C5 and C6 dermatomes. He was diagnosed to have herpes zoster and was started on oral antiviral therapy. Four days later he developed multiple new flaccid bullae adjacent to the preexisting lesions along the same dermatome with a positive Nikolsky sign (Figure 1). He did not have vesicles or bulla anywhere else in the body. Hence a possibility of dermatomal pemphigus vulgaris occurring concurrently with herpes zoster was considered.

Tzanck smear was done from two sites which revealed several multinucleate giant cells along with a few acantholytic cells (Figure 2). Skin biopsy taken from the new flaccid bullous lesion showed a suprabasal bulla in the epidermis with the basal layer showing a 'row of tomb stones appearance'. Direct immunofluorescence revealed intercellular deposition of antibodies in a fishnet pattern (Figure 3a and Figure 3b). Routine hematological investigations were normal. Tests for detecting Varicella-Zoster viral DNA from the blister fluid were not done.

A diagnosis of herpes zoster of left C5, C6 dermatomes associated with pemphigus vulgaris localizing in the same dermatomes was made based on the above clinical and laboratory findings.

**DISCUSSION:** The term isotopic response refers to the occurrence of a new skin disorder at the site of another, unrelated, and already healed skin disease. It was first defined by Wolf et al in 1985 and

## CASE REPORT

---

hence known as Wolf's isotopic response. It is also called Isoloci response.<sup>1,2</sup> The various etiological factors considered for this phenomenon include viral, immunological, neural, vascular and locus minoris resistentiae (A site of decreased resistance).<sup>3,4</sup>

Several dermatological conditions have been reported to exhibit this response, most of which have occurred over scars of herpes zoster and rarely over herpes simplex or thrombophlebitis.<sup>9</sup> The usual second dermatoses include granuloma annulare, sarcoidosis, lichen planus, multiple epidermoid cysts, granulomatous folliculitis, and tinea infections etc.<sup>5,6,7</sup> Some authors have discussed a case of varicella lesions localizing at the site of pyoderma. This was considered to be a variant of the isotopic phenomenon.<sup>8</sup> Zosteriform pemphigoid developing after Herpes Zoster on the scars has recently been reported.<sup>10</sup>

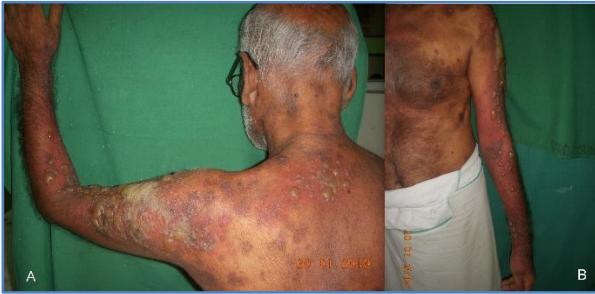Many patients of pemphigus on steroids and immunosuppressive therapy can develop Herpes Zoster while on treatment. Our patient was a case of Pemphigus in remission and not currently on any medication. The interesting feature in our patient is the localization of pemphigus lesions to the dermatomes involved by herpes zoster without involving any other skin or mucosal surface. It may be possible in this case that Herpes zoster might have triggered the release of cytokines and interferons, leading to over activation of the immune system and caused the dormant underlying Pemphigus vulgaris to clinically manifest.

The importance of doing a simple bedside Tzanck smear in blistering disorders is very evident here, as the presence of both primary and secondary acantholysis could be demonstrated in the same smear. Patient was successfully treated with valcyclovir 1000mg thrice a day for 10 days and prednisolone 20mg daily along with other supportive measures. This rare entity of co-localization of two active blistering dermatoses involving pemphigus vulgaris occurring only over an active herpes zoster infection has not been reported in the literature so far.

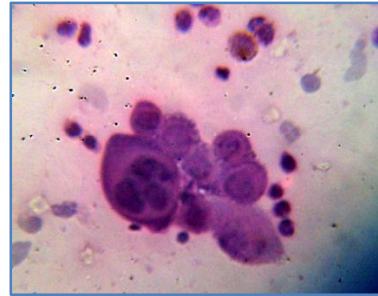
### REFERENCES:

1. Wolf R, Brenner S, Ruocco V, Filoli FG. Isotopic response. *Int J Dermatol* 1995; 34: 341-8.
2. Wolf R, Wolf D. Tinea in a site of healed herpes zoster (Isoloci response). *Int J Dermatol* 1985; 24: 539
3. Thappa D. Isotopic responses versus isomorphic response. *Indian J Dermatol Venerol Leprol* 2004; 70: 376.
4. Jackson R. Observation on the site, size, shape and arrangement of lesions in the human skin. *Int J Dermatology* 1984; 23: 370-374.
5. Sandhu K, Saraswat A, Handa S. Multiple epidermoid cysts occurring at site of healed herpes zoster in a renal transplant recipient: An isotopic response? *Clin Exp Dermatol* 2003; 28: 555-6.
6. Fernandez-Redondo V, Amrouni B, Varela E, Toribio J. Granulomatous folliculitis at sites of herpes zoster scars: Wolf's isotopic response. *J Eur Acad Dermatol Venereol* 2002; 16: 628-30.
7. Turel A, Ozturkcan S, Sahin MT, Turkdogan P. Wolf's isotopic response: A case of zosteriform lichen planus. *J Dermatol* 2002; 29: 339-42.
8. Ravikumar BC, Balachandran C. Localisation of varicella lesions around pyoderma. A distinct phenomenon. *Indian J Dermatol Venerol Leprol* 1999; 65: 36-7.
9. Requena L, Kutzner H et al. Cutaneous reactions at sites of herpes zoster scars: an expanded spectrum. *Br J Dermatol*.1998; 138: 161-8.

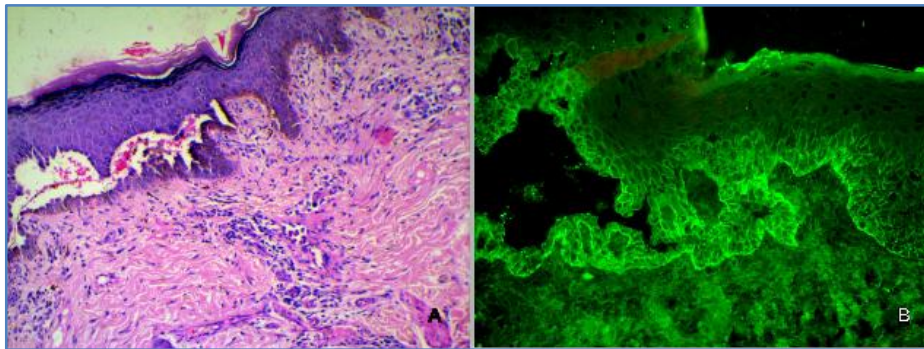
# CASE REPORT



**Fig. 1**



**Fig. 2**



**Fig. 3A & B**

## **AUTHORS:**

1. Murali Narasimhan
2. Subashini Karthikeyan
3. Pushpa Gnanaraj
4. Venugopal Vakati

## **PARTICULARS OF CONTRIBUTORS:**

1. Associate Professor, Department of Dermatology, SRM Medical College & Research Centre, Potheri.
2. Consultant Dermatologist, Department of Dermatology, SRM Medical College & Research Centre, Potheri.
3. Consultant Dermatologist, Department of Dermatology, SRM Medical College & Research Centre, Potheri.

## **FINANCIAL OR OTHER**

**COMPETING INTERESTS:** None

4. Consultant Dermatologist, Department of Dermatology, SRM Medical College & Research Centre, Potheri.

## **NAME ADDRESS EMAIL ID OF THE CORRESPONDING AUTHOR:**

Dr. Murali Narasimhan,  
#114 Venkatrangam Street,  
Triplicane, Chennai-600005.  
E-mail: leecutis@rediffmail.com

Date of Submission: 03/07/2015.  
Date of Peer Review: 04/07/2015.  
Date of Acceptance: 20/07/2015.  
Date of Publishing: 27/07/2015.